Persistent Left Superior Vena Cava:

Chest X-Ray and Echocardiographic Findings

Marie Dearstine, R.D.C.S.,* Wayne Taylor, RT(R),† and Edmund K. Kerut, M.D.‡§#

*Cardiology Department and †Cardiopulmonary and Invasive Cardiology, Meadowcrest Hospital, Gretna, ‡Echocardiography Laboratory, Heart Clinic of Louisiana, Marrero, §Cardiovascular Research Laboratory, LSU School of Medicine, New Orleans, and #Clinical Associate Professor of Medicine, Tulane University, School of Medicine, New Orleans, Louisiana

Case Report

A 74-year-old woman presented with progressive dyspnea and renal failure. A central line catheter was inserted percutaneously into the left internal jugular vein in the emergency department. A chest X ray was performed to document the position of the central line catheter (Fig. 1), and revealed an unusual coarse, suggesting the possibility of a persistent left superior vena cava (PLSVC).

After admission to the intensive care unit, transthoracic echocardiography with peripheral saline contrast injection in the right antecubital vein (Fig. 2), and also the left antecubital vein (Fig. 3), was performed. Injection of saline contrast into the right antecubital vein documented contrast entering the right atrium via the normal left superior vena cava. However, injection of saline contrast into the left antecubital vein resulted in contrast first appearing in the coronary sinus, followed by the right atrium.

Discussion

A PLSVC with connection to the coronary sinus is a relatively common finding. It occurs in 0.3%–0.5% of the general population and in up to 10% of patients with congenital heart disease.[1-3] The echocardiographic and saline contrast features have previously been well-described.[4] Usually, a normal right superior vena cava is present. A PLSVC with connection to the coronary sinus is of no hemodynamic consequence, but is of importance when a patient is on cardiac bypass, as coronary sinus flow must be cannulated, along with the usual cannulation of venous return from the superior and inferior venae cavae.

In this case, making a diagnosis of PLSVC by echocardiography explained the unusual course of the left internal jugular vein catheter that was found on the admission chest X ray. By making a diagnosis of PLSVC by echocardiography, the unnecessary removal of the central line catheter and subsequent second central line placement procedure was avoided.

Address for correspondence and reprints: Marie Dearstine, R.D.C.S., Cardiology Department, Meadowcrest Hospital, 2500 Belle Chasse Highway, Gretna, LA 70056.

References

1. Buirski G, Jordan S, Joffe HS, et al: Superior vena caval abnormalities: Their occurrence rate, associated cardiac abnormalities and angiographic classification in a paediatric population with congenital heart disease. *Clin Radiol* 1986;37:131.
2. Mazzucco A, Bortolotti U, Stellin G, et al: Anomalies of systemic venous return: A review. *J Card Surg* 1990; 5:122.
3. Mantini E, Grondin CM, Lillehei CW, et al: Congenital anomalies involving the coronary sinus. *Circulation* 1966;33:317.
4. Stewart JA, Fraker TD, Slosky DA, et al: Detection of persistent left superior vena cava by two-dimensional contrast echocardiography. *J Clin Ultrasound* 1979;7: 357.

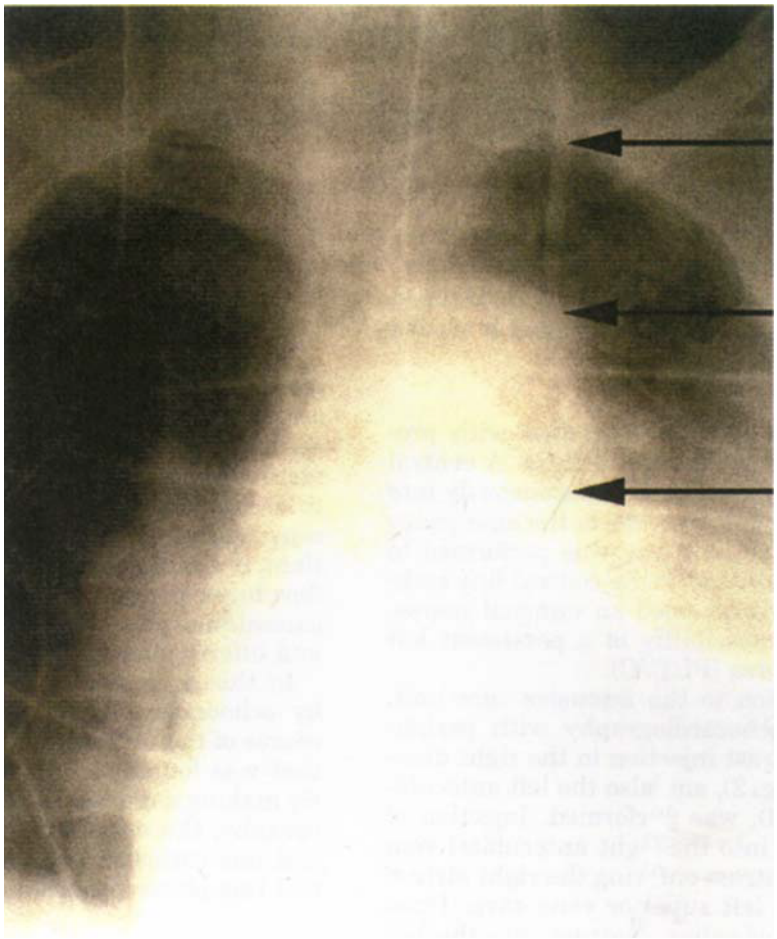

Figure 1. *Portable AP chest X-ray after insertion of a left internal jugular vein central line catheter. Arrows point to the unusual course of the catheter within a persistent left superior vena cava.*

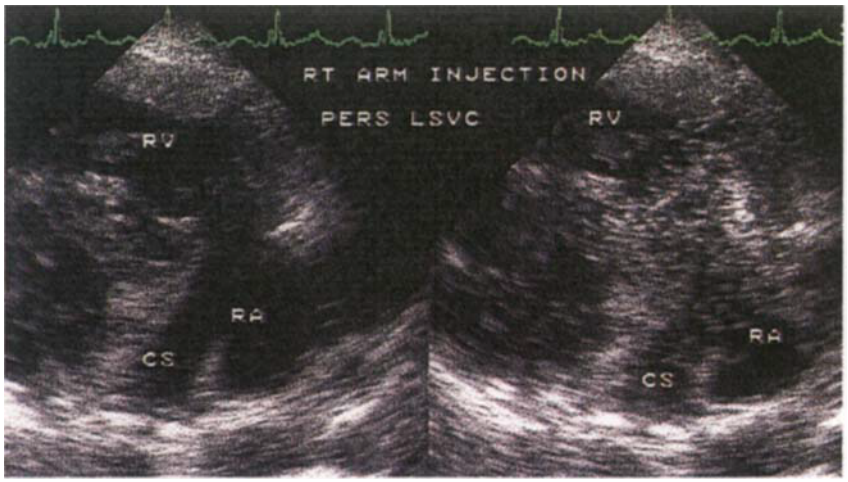

Figure 2. *Parasternal right ventricular inflow view. A baseline image is on the left. Peripheral saline contrast injection via the right antecubital vein is noted to enter the right heart in the image on the right. The coronary sinus remained nonopacified. RA = right atrium; RV = right ventricle; CS = coronary sinus.*

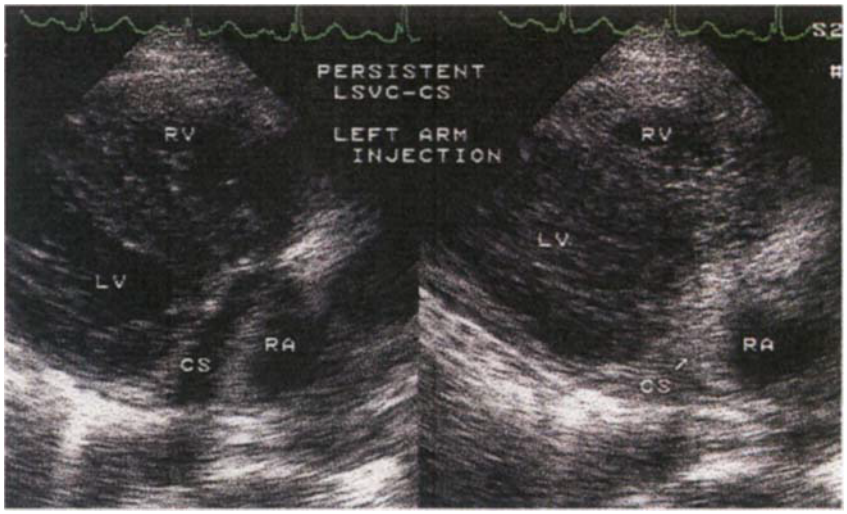

Figure 3. *Parasternal right ventricular inflow view. A baseline image is on the left. This time peripheral saline contrast injection is performed via the left antecubital vein. The coronary sinus was seen to opacify first, followed by the right heart. RA = right atrium; RV = right ventricle; LV = left ventricle; CS = coronary sinus.*